Brain Stimulation 11 (2018) 947–948

Contents lists available at ScienceDirect

Brain Stimulation

journal homepage: http://www.journals.elsevier.com/brain-stimulation

Tragus or cymba conchae? Investigating the anatomical foundation of transcutaneous auricular vagus nerve stimulation (taVNS)

Bashar W. Badran [a, b, c, *], Joshua C. Brown [a], Logan T. Dowdle [a], Oliver J. Mithoefer [a], Nicholas T. LaBate [d], James Coatsworth [e], William H. DeVries [a], Christopher W. Austelle [a], Lisa M. McTeague [a], Alfred Yu [c], Marom Bikson [b], Dorothea D. Jenkins [f], Mark S. George [a, g, h]

[a] Brain Stimulation Lab, Medical University of South Carolina, Charleston, SC, USA
[b] Department of Biomedical Engineering, City College of New York, New York, NY, USA
[c] U.S. Army Research Lab, Aberdeen Proving Ground, MD, USA
[d] College of Charleston, Charleston, SC, USA
[e] Center for Biomedical Imaging, Medical University of South Carolina, Charleston, SC, USA
[f] Department of Pediatrics, Medical University of South Carolina, Charleston, SC, USA
[g] Department of Neurology, Medical University of South Carolina, Charleston, SC, USA
[h] Ralph H. Johnson VA Medical Center, Charleston, SC, USA

ARTICLE INFO

Article history:
Received 5 June 2018
Accepted 5 June 2018
Available online 6 June 2018

Keywords:
tVNS
taVNS
Tragus
Cymba conchae
Auricular vagus

Dear Editor

We thank Burger and Verkuil [1] for bringing attention to the only published cadaver ear dissection studies in the literature, published in 2002 by Peuker and Filler [2]. This cadaver study is indeed important, and has fueled the increased interest in modulating the auricular branch of the vagus nerve (ABVN). Researchers clearly want to know which ear target is optimal for taVNS – tragus or cymba conchae? Burger and Verkuil have found and investigated an apparent discrepancy in Peuker and Filler's work, and then contacted Prof. Filler for clarification. Unfortunately, this discrepancy was difficult to resolve. We have several comments.

First, although the Peuker and Filler manuscript is important, there are other studies describing vagus innervation of the ear, best exemplified with the Eastern medicine field of therapeutic auricular acupuncture. Auricular acupuncture has been used for centuries and these studies add to this body of information [3–5]. Thus, it is critical to acknowledge that the field of taVNS does not necessarily rest on one table in one manuscript.

Second, we do not necessarily see the same conflict. See the figure from Peuker and Filler (Fig. 1a) as well as a complementary figure from He et al. (Fig. 1b). Although the arrow of the ABVN is unclear and may point to the tragus as well as the conchae, the table (Fig. 1c) describes the vagus as being 45% innervated by the ABVN (with the conchae having 100% of its fibers from the vagus, but slightly more proximal). Both locations likely engage some vagus fibers. Although the cymba conchae targets may be 100% innervated by the ABVN according to the table, ABVN fibers innervate the anterior wall of the external ear canal, landmarked by the tragus. The tragus also offers some advantages in terms of ease of applying electricity to the anterior wall of the external ear canal by being able to clip onto the tragus, as opposed to having to insert and hold an electrode against the conchae.

Finally, our imaging study, and others [6,7], combined with heart rate data in adults [8] and now infants (Badran, Jenkins et al., under review, Brain Stimulation) indicate that tragus stimulation engages vagal afferents. Other groups have also demonstrated vagus sensory evoked potentials (VSEP) from tragus stimulation [9] as well as heart rate variability and reduced sympathetic activity [10].

We agree, however, with Burger and Verkuil that we do not know the absolute best ear target for taVNS, as the innervation of the ABVN remains unclear. More anatomical dissection studies

* Corresponding author. MUSC Institute of Psychiatry, 67 President St., 504N Charleston, SC, 29425, USA.
E-mail address: basharwbadran@gmail.com (B.W. Badran).

https://doi.org/10.1016/j.brs.2018.06.003

a

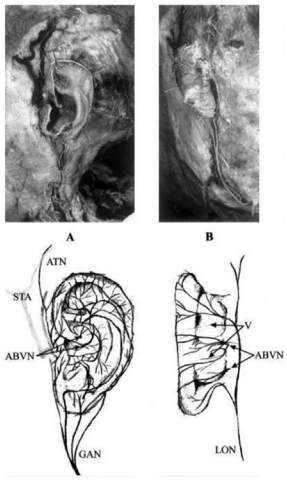

Fig. 2. **A.** Lateral surface of the external ear with corresponding scheme. ABVN = auricular branch of vagus nerve; GAN = great auricular nerve; ATN = auriculotemporal nerve; STA = superficial temporal artery. **B.** Medial surface of the external ear with corresponding scheme. ABVN = auricular branch of vagus nerve; LON = lesser occipital nerve; V = vessels.

Peuker & Filler

b

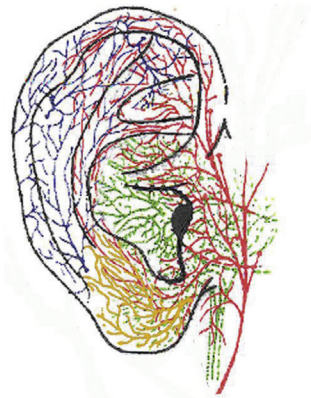

FIGURE 1: The innervations of the external auricle. The innervations of the auricular branch of the vagus nerve are marked by green color. The innervations of the auriculotemporal nerve are marked by red color. The innervations of the lesser occipital nerve are marked by blue color. The innervations of the greater auricular nerve are marked by yellow color.

He et al.

c

TABLE 1. Overview of the Innervation Pattern of the Lateral Surface of the Auricle

	ABVN	GAN	ATN
Crus of helix	20%		80%
Spine of helix		9%	91%
Tail of helix		100%	
Scapha		100%	
Crura of anthelix	9%	91%	
Antihelix	73%	9%	18%
Antitragus		100%	
Tragus	45%	46%	9%
Cymba conchae	100%		
Cavity of concha	45%	55%	
Lobule of auricle		100%	

ABVN = auricle branch of the vagus nerve; GAN = great auricular nerve; ATN = auriculotemporal nerve.

Peuker & Filler

Fig. 1. Figures and table taken and reproduced here from the initial Peuker & Filler cadaver paper (a,c) as well as an anatomical drawing from He et al. (b) demonstrating ABVN innervation of the human ear.

would help resolve this inconsistency and we hope that this correspondence spurs further research. These cadaver studies should be conducted by individuals with advanced training in microdissection of the head and neck, as the ABVN diameter is on a micrometer resolution. Teams should also consider age, ethnicity, trauma, and prior health history in their selection of cadavers. A large, diverse, cross-section of individuals would aid in optimizing taVNS.

Advanced *In Vivo* peripheral nerve imaging using high-resolution ultrasonography (US) may also be used to track nerve innervation, although poor resolution may be a limitation. Alternatively, the magnetic resonance imaging (MRI) scanning protocol known as diffusion tensor imaging (DTI) could potentially be used to image the peripheral nerves. *In vivo* imaging approaches might eventually permit individualized ABVN targeting and placement of taVNS.

In order to optimize noninvasive brain stimulation modalities as therapeutics, it is critical to consider 4 basic fundamentals: 1) anatomy; 2) target engagement; 3) parameter space; and 4) behavioral effects. taVNS is still in its infancy with groups investigating target and parameter engagement via central [6,7,9] and peripheral [8,10] biomarkers. Behavioral effects are being demonstrated in numerous neuropsychiatric disorders. We need more work on the anatomical basis of taVNS in order to better guide our future trials.

Conflicts of interest

We wish to confirm that there are no known conflicts of interest associated with this publication and there has been no significant financial support for this work that could have influenced its outcome. We further confirm the order of authors listed in this manuscript has been approved by all of us and that the work described in this manuscript is not currently under consideration for publication in another journal.

References

[1] Burger AM, Verkuil B. Transcutaneous nerve stimulation via the tragus: are we really stimulating the vagus nerve? Brain Stimul 2018 ISSN: 1935-861X. https://doi.org/10.1016/j.brs.2018.03.018 (in press).
[2] Peuker ET, Filler TJ. The nerve supply of the human auricle. Clin Anat 2002;15(1):35–7.
[3] He W, Wang X, Shi H, Shang H, Li L, Jing X, et al. Auricular acupuncture and vagal regulation. Evid base Complement Alternat Med 2012;2012, 786839.
[4] Usichenko T, Hacker H, Lotze M. Transcutaneous auricular vagal nerve stimulation (taVNS) might be a mechanism behind the analgesic effects of auricular acupuncture. Brain Stimul 2017;10(6):1042–4.
[5] Asher GN, Jonas DE, Coeytaux RR, Reilly AC, Loh YL, Motsinger-Reif AA, et al. Auriculotherapy for pain management: a systematic review and meta-analysis of randomized controlled trials. J Alternative Compl Med 2010;16(10):1097–108.
[6] Badran BW, Dowdle LT, Mithoefer OJ, LaBate NT, Coatsworth J, Brown JC, et al. Neurophysiologic effects of transcutaneous auricular vagus nerve stimulation (taVNS) via electrical stimulation of the tragus: a concurrent taVNS/fMRI study and review. Brain Stimul May–June 2018;11(3):492–500.
[7] Yakunina N, Kim SS, Nam EC. Optimization of transcutaneous vagus nerve stimulation using functional MRI. Neuromodulation: technology at the neural interface. 2016.
[8] Badran BW, Mithoefer OJ, Summer CE, LaBate NT, Glusman CE, Badran AW, et al. Short trains of transcutaneous auricular vagus nerve stimulation (taVNS) have parameter-specific effects on heart rate. Brain Stimulation 2018 ISSN: 1935-861X. https://doi.org/10.1016/j.brs.2018.04.004 (in press).
[9] Fallgatter A, Neuhauser B, Herrmann M, Ehlis A-C, Wagener A, Scheuerpflug P, et al. Far field potentials from the brain stem after transcutaneous vagus nerve stimulation. J Neural Transm 2003;110(12):1437–43.
[10] Clancy JA, Mary DA, Witte KK, Greenwood JP, Deuchars SA, Deuchars J. Non-invasive vagus nerve stimulation in healthy humans reduces sympathetic nerve activity. Brain stimulation 2014;7(6):871–7.